

**Patient Information**

**Patient ID:** JAD-MAY19-01  
**Patient Name:** Jane Doe  
**Date of Birth:** 20-Jan-1970  
**Gender:** Female  
**Submission Date:** 2019-May-03 10:44

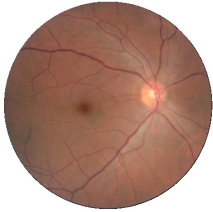**General Information**

**Referring Location:** Eyenuk Inc  
**Referring Provider:** Dr. Karla Sanders  
**Encounter ID:** 01  
**EyeArt Control ID:** 123893  
**Dilation Status:** Non Dilated

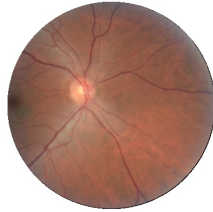**Diabetic Retinopathy Screening Summary**

**Screening Result:** Negative for referable diabetic retinopathy.

**Right Eye:** No apparent signs of DR detected [0.0]

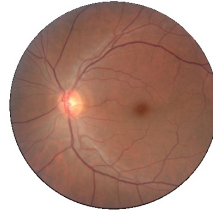


Macula Centered

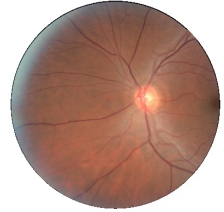

ONH Centered

**Left Eye:** No apparent signs of DR detected [0.0]



Macula Centered



ONH Centered

\*Do not use the above thumbnail images for diagnostic purposes.

**ICD-10 Diagnosis Codes**

**E10.9** Type 1 diabetes mellitus without complications

**Plan and Recommendations**

Return for retinal imaging within 12 months.

As per ADA recommendations, emphasize the importance of controlling blood sugar, cholesterol and blood pressure as well the importance of routine follow-up with an ophthalmologist regardless of whether visual symptoms are present or absent.

**Comments**

**Left Eye:** None

**Right Eye:** None

Report Date: 2019-May-03 10:45